

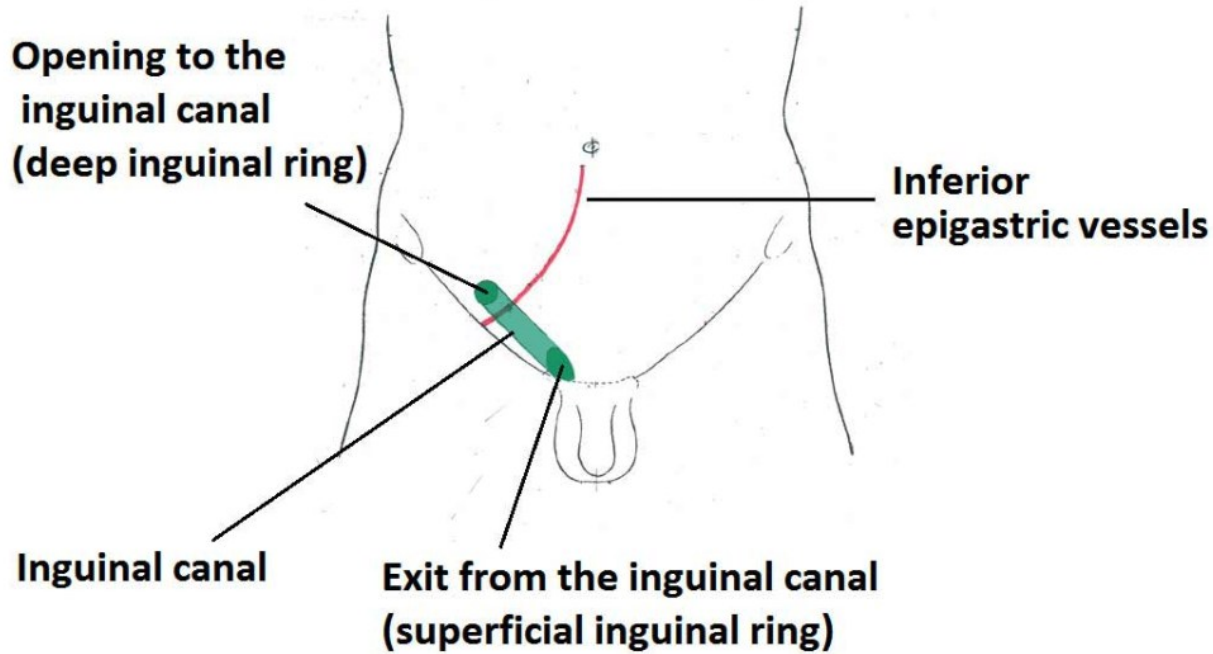
# **ANATOMY OF INGUINAL CANAL**

**DR GANGADHAR CH  
III YEAR PG  
DEPT OF ANATOMY  
KIMS, NKP**

# **CONTENTS**

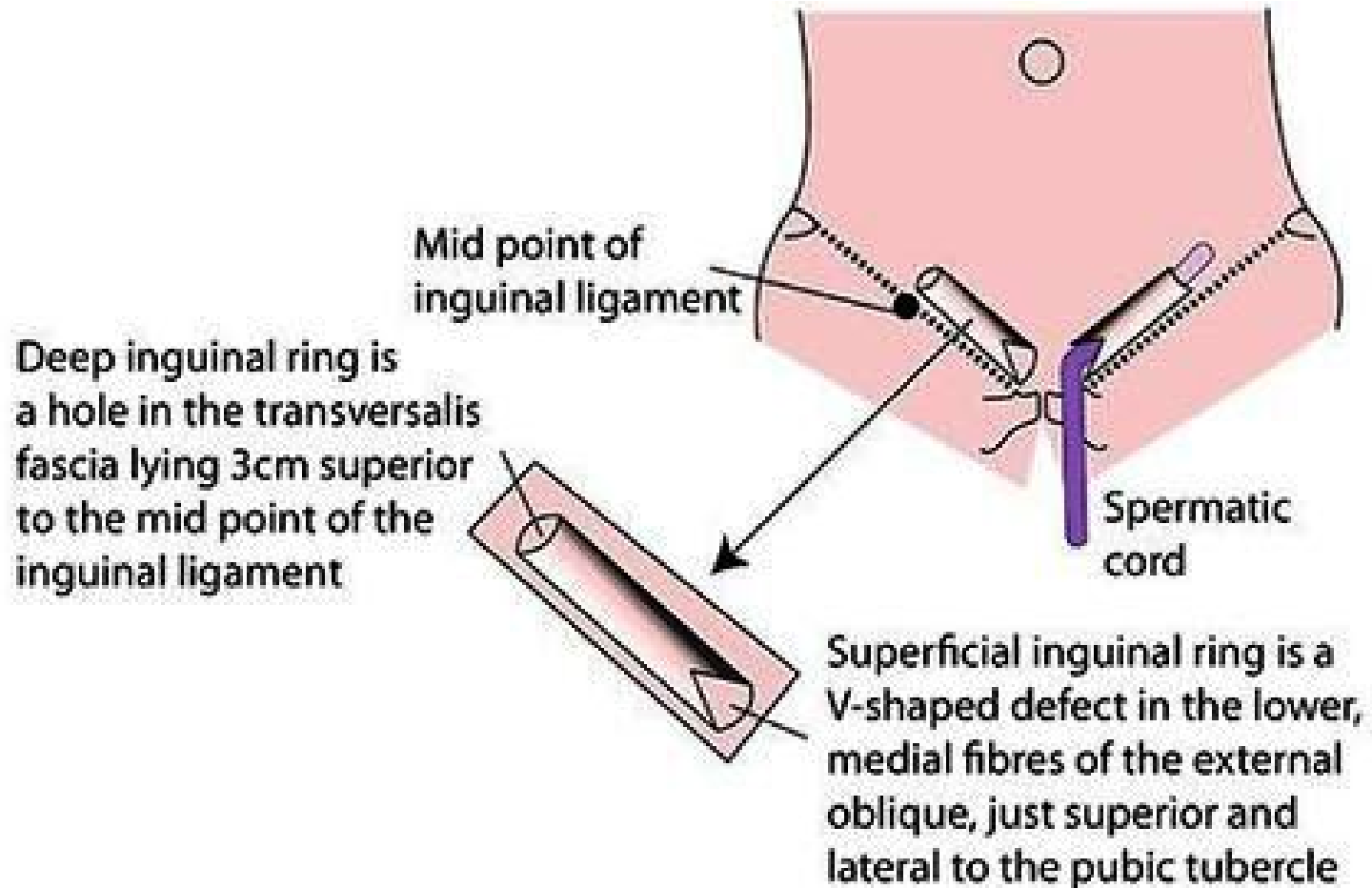
- **INTRODUCTION TO INGUINAL CANAL**
- **LOCATION & EXTENT OF INGUINAL CANAL**
- **BOUNDARIES OF INGUINAL CANAL**
- **DEFENSIVE MECHANISMS OF INGUINAL CANAL**
- **APPLIED**

# INTRODUCTION OF INGUINAL CANAL

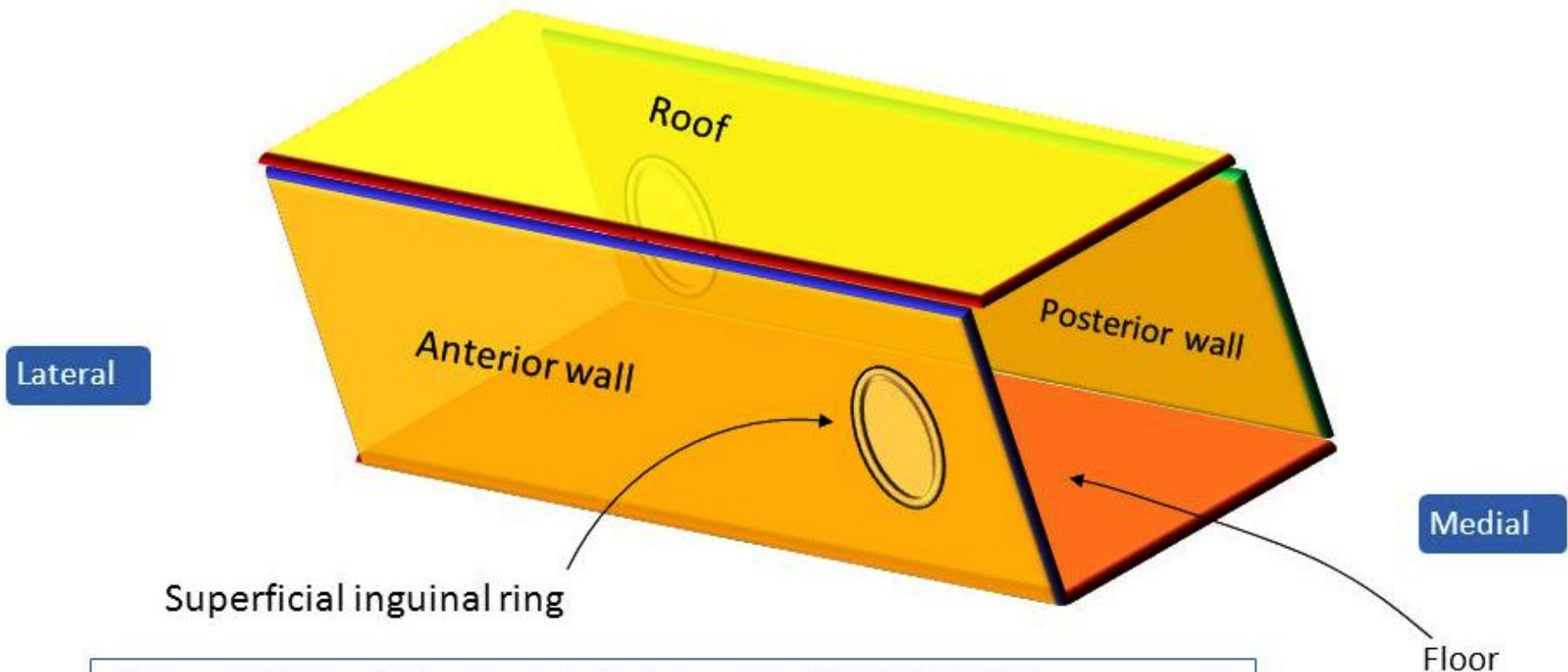


It is an oblique passage through the lower part of the anterior abdominal wall. It is about 4 cm long in adult and extends from the deep inguinal ring, downward and medially to the superficial inguinal ring. It lies parallel to and immediately above the inguinal ligament.

# LOCATION & EXTENT OF INGUINAL CANAL



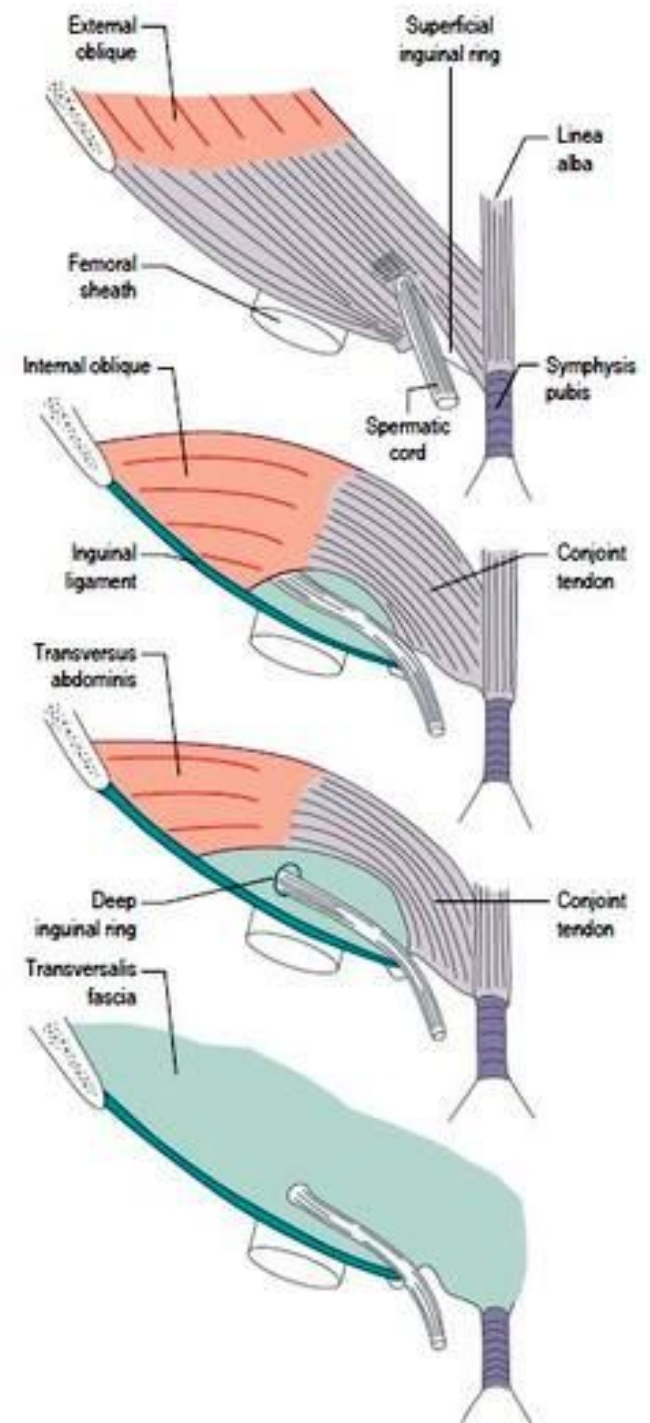
# BOUNDARIES OF INGUINAL CANAL



Here are the anterior wall (which has the SUPERFICIAL inguinal ring situated medially), and the roof.

# Inguinal Canal Anatomy

- **Anterior wall:**
  - aponeurosis of external oblique (along entire length),
  - internal oblique on lateral one third
- **Posterior:**
  - fascia transversalis
  - conjoint tendon in medial one third
- **Roof:**
  - arching fibers of internal oblique, and
  - transversus abdominis
- **Floor (inferior):**
  - inguinal ligament, and
  - lacunar ligament at the medial end



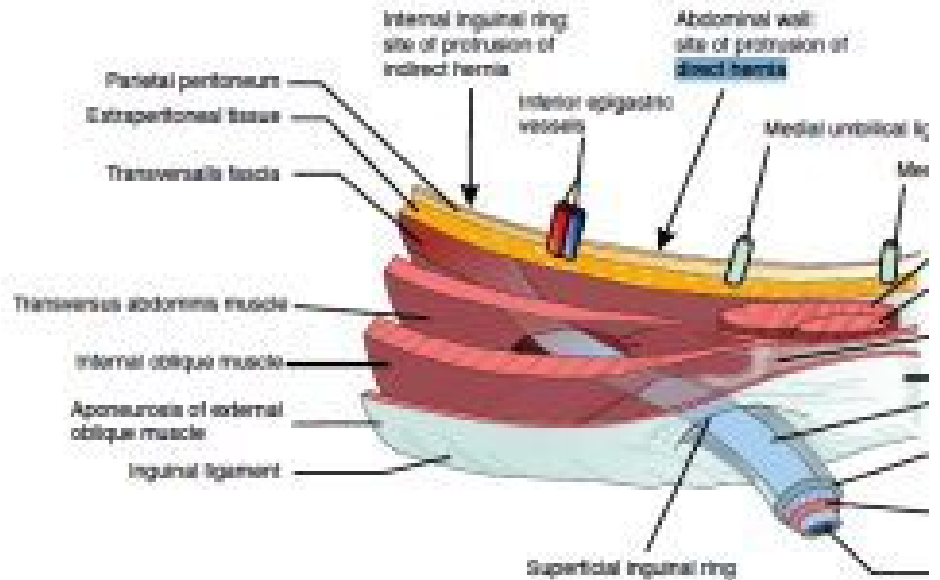
# DEFENSIVE MECHANISMS OF INGUINAL CANAL

Oblique trajectory.

Anterior wall reinforced laterally by the internal oblique in front of the deep ring.

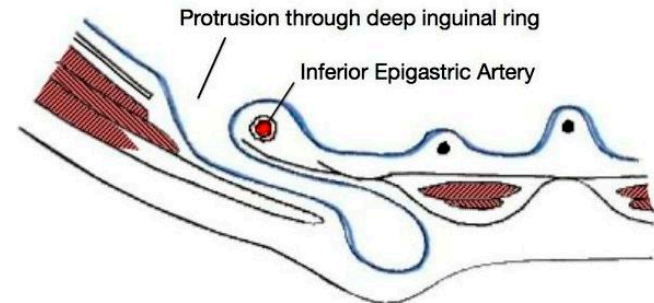
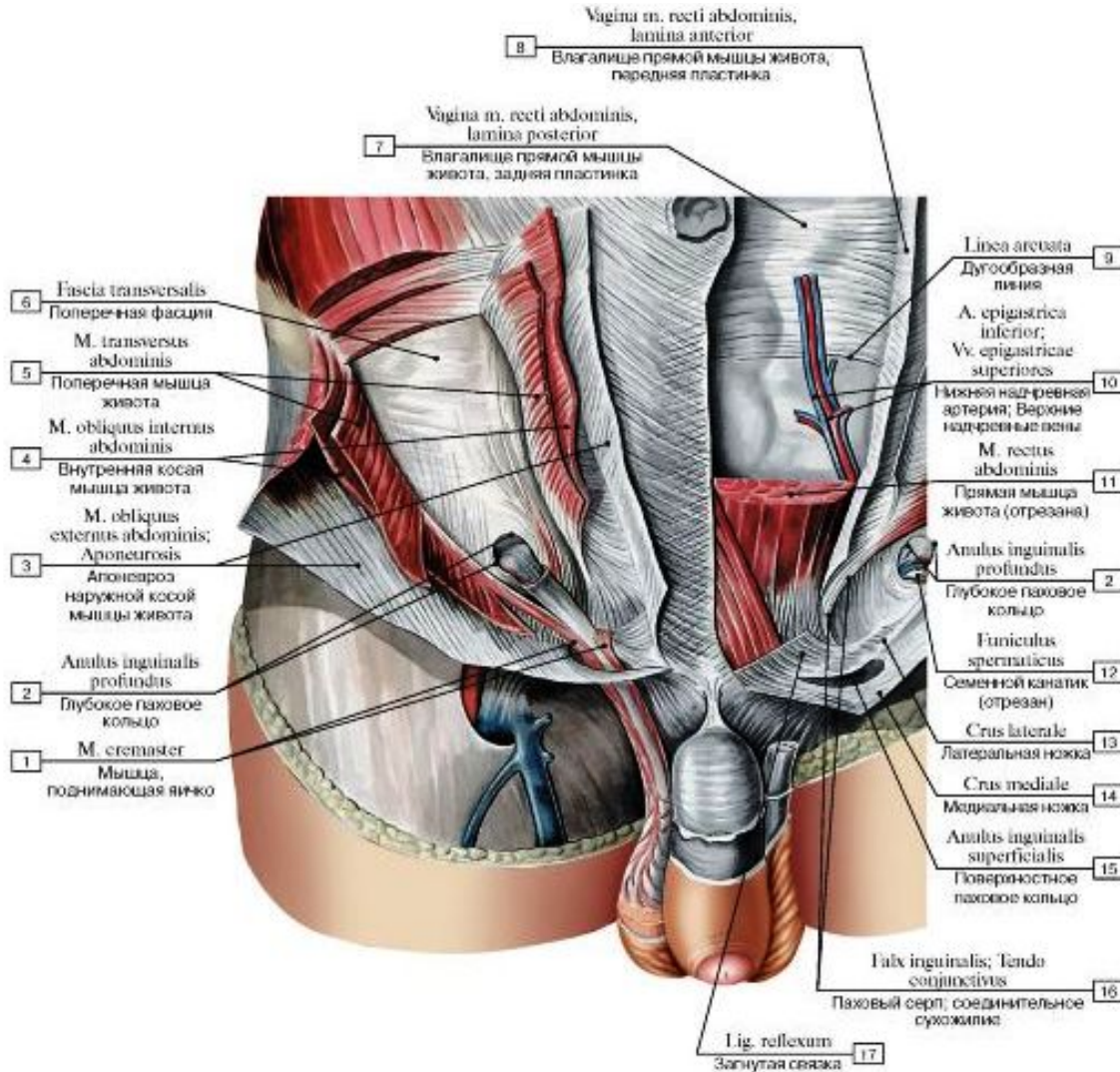
Posterior wall reinforced medially by the conjoint tendon behind the superficial ring.

On coughing and straining (micturition and defecation) the arching lower fibers of the internal oblique and transversus abdominis contract and flatten the roof of the canal, compressing its content.

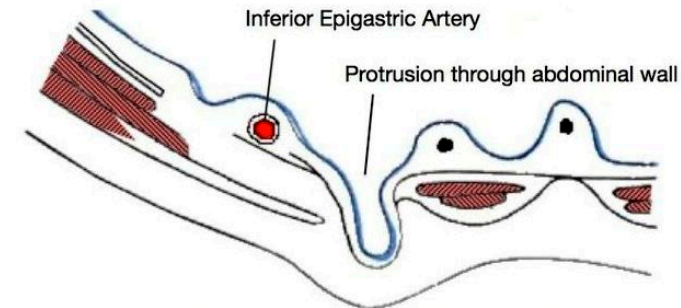




# APPLIED



**A. Indirect Inguinal Hernia**



**B. Direct Inguinal Hernia**



**THANK YOU**