

# FUNGAL CORNEAL ULCER

CASE PRESENTATION

BY

Dr. Prashanti

OPHTHALMOLOGY Ist YR

# PERSONAL DETAILS

- NAME : xxx
- AGE :57
- SEX : Male
- IP/OP NO- 20170828623
- OCCUPTION : Farmer

# CHIEF COMPLAINTS

- Redness
- Pain
- Watering
- Blurring of vision

Since one week in the left eye

# HISTORY OF PRESENT ILLNESS

- Patient was apparently asymptomatic 1 week back, after which he sustained an injury to the left eye with vegetative matter while working in the farm
- He developed redness and pain followed by watering associated with blurring of vision and photophobia which were insidious in onset and gradually progressed to the present stage.
- No history of colored halos, diurnal variation of symptoms or pain on moving the eyeball.

# PAST HISTORY

- MEDICAL : no history of diabetes, hypertension, bronchial asthma, TB, or epilepsy
- DRUG HISTORY : no history of usage of topical medication or any drug allergies.
- OCULAR SURGERIES : Patient underwent manual small incision cataract surgery in both eyes.
  - Right eye : 3 years back
  - Left eye : 1 year back
- FAMILY HISTORY : Not significant
- PERSONAL HISTORY : Mixed diet, sleep and appetite were normal, regular bowel and bladder habits.

# GENERAL EXAMINATION

- Patient was conscious, coherent and cooperative
- Temperature : afebrile
- Pulse rate : 76bpm
- Blood pressure : 110/80 mm of hg
- No pallor, icterus , cyanosis, clubbing, lymphadenopathy or peripheral oedema.

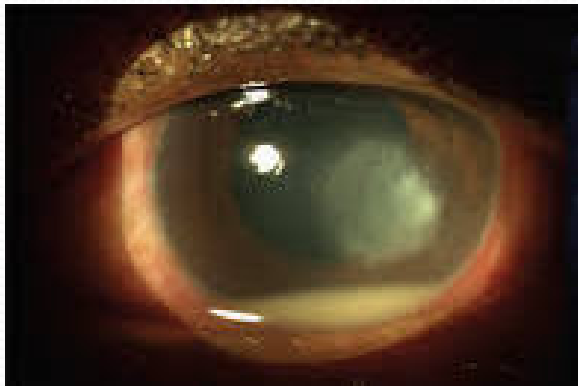# SYSTEMIC EXAMINATION

- RESPIRATORY SYSTEM : Bilateral normal vesicular breath sounds heard
- CVS : S<sub>1</sub> and S<sub>2</sub> heard, no murmurs
- CNS : Normal
- PER ABDOMEN : Soft

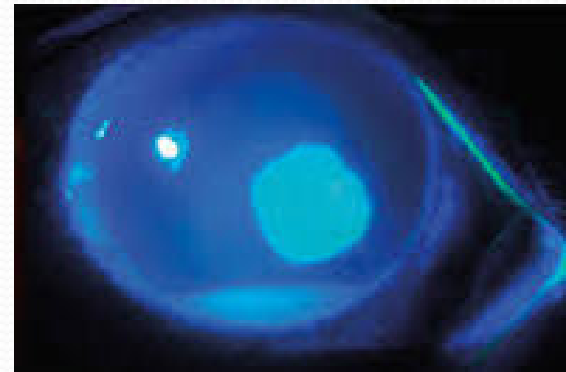
	RIGHT EYE	LEFT EYE
VISUAL ACUITY	6/12 with pinhole 6/9	6/60 with pinhole NI
LIDS	Normal	Oedematous
CONJUNCTIVA	Normal	Congested, circum ciliary congestion +
CORNEA	Clear	A single ulcer of size 3x4mm between 3-6'o clock position feathery margins , sloping edges , yellowish -white slough in the base of the ulcer +, stromal infiltrates+ stomal Oedema +
ANTERIOR CHAMBER	Normal depth	Hypopyon of 1-2mm height, non-mobile
IRIS	Normal colour pattern	Normal colour pattern
PUPIL	Normal size, reacting to light	Mid dilated ,sluggish
LENS	Pseudophakia	Pseudophakia



- DIFFUSE ILLUMINATION



- FLUORESCCEIN STAINING



# FUNDUS EXAMINATION

- RIGHT EYE : Disc – normal size, circular, pink, well defined margins  
CDR – 0.3: 1  
AVR – 2:3  
Vessels – normal  
Macula – Foveal reflex +
- LEFT EYE : Could not be made out due to hazy cornea
- LACRIMAL SYRINGING : Both eyes patent.

# INVESTIGATIONS

- RBS : 120mg/dl
- Complete Urine Examination : Normal
- Complete Blood Picture : Within normal limits

# SPECIAL INVESTIGATIONS

## CORNEAL SCRAPINGS

- Gram's stain : gram +ve
- KOH mount : filamentary elements with septate hyphae seen



# DIAGNOSIS

LEFT EYE FUNGAL CORNEAL ULCER WITH  
HYPOPYON

# TREATMENT – DAY 1

- E/d 5% Natamycin – hourly
- E/d 0.3% Moxifloxacin – 6td
- E/d 2% Homatropine – 3td
- Tab Fluconazole 200mg BD
- Tab Acetazolamide 250mg BD
- Tab Ibuprofen 400mg BD
- Tab Ranitidine 150mg BD

# DAY 3

- E/d 5% Natamycin – hourly
- E/d 0.3% Moxifloxacin – 6td
- E/d 2% Homatropine – 3td
- Tab Fluconazole 200mg BD
- Tab Acetazolamide 250mg BD
- Tab Ibuprofen 400mg BD
- Tab Ranitidine 150mg BD

# DAY 5

- E/d 5% Natamycin– 8td
- E/d 0.3% Moxifloxacin – 6td
- E/d 2% Homatropine – 3td
- Tab Fluconazole 200mg BD
- Tab acetazolamide 250mg BD
- Tab Ibuprofen 400mg BD
- Tab Ranitidine 150mg BD



# DAY 7

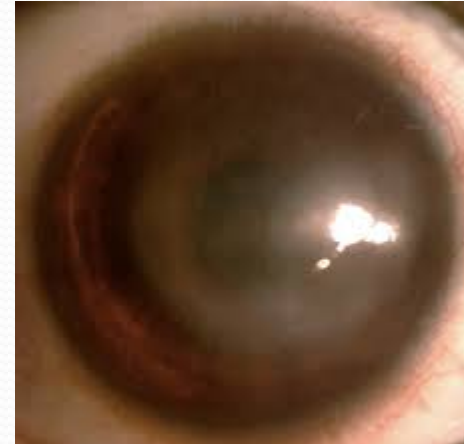- E/d 5% Natamycin – 6td
- E/d 0.3% Moxifloxacin – 6td
- E/d 2% Homatropine – 3td
- Tab Fluconazole 200mg BD
- Tab Ibuprofen 400mg BD
- Tab Ranitidine 150mg BD

# DAY 9

- E/d 5% Natamycin – 4td
- E/d 0.3% Moxifloxacin – 6td
- E/d 2% Homatropine – 3td
- Tab Fluconazole 200mg BD

# DAY 10

- E/d 5% Natamycin – 4td
- E/d 0.3% Moxifloxacin – 6td
- Tab Fluconazole 200mg BD



# TREATMENT ON DISCHARGE

- E/d 5% Natamycin 2td
- E/d 0.3% Moxifloxacin 6td
  
- Review after 1 week

# ON REVIEW

	RIGHT EYE	LEFT EYE
VISUAL ACUITY	6/12 with pinhole 6/9	6/60 with pinhole 6/24
LIDS	Normal	Normal
CONJUNCTIVA	Quiet	Quiet
CORNEA	Clear	2mm macular opacity +
ANTERIOR CHAMBER	Normal in depth	Normal in depth
IRIS	Normal colour pattern	Normal colour pattern
PUPIL	Normal size, reacting to light	Normal size, reacting to light
LENS	Pseudophakia	Pseudophakia

**THANK YOU**