

2 Cases of Acute abdomen

By

Dr Ramesh Krishna B

PG, Gen Med

Date: 10, April, 2014

- A 54 year old female patient resident of chityal, has come to the casualty with the chief complaints of pain abdomen and vomiting since 2 days.

History of present illness:

- Abdominal pain gradual in onset, increasing in severity, throbbing in nature, epigastric in region, radiating to the back, it has no relation to food and relieves on sitting and leaning forward.

- Patient had vomiting 2 to 3 episodes per day since 2 days, non projectile and non bilious and contain food particles.
- She has no history of jaundice and no history of abdominal distension.
- No history of fever, headache, loose stools or constipation.

Past history:

- She had no history of similar complaints in the past.
- She is a known diabetic since 10 years on Inj human mixtard 12 units in the morning and 8 units in the night.
- She is not using the insulin for the last 5 days.

- She is not a known hypertensive
- She has no history of gall stone disease, tuberculosis, asthma, epilepsy.
- No history of previous abdominal surgeries except for the tubectomy 28 years back.

Personal history:

- She is an occasional alcoholic but not a smoker
- Bowel and bladder habits are regular.
- Appetite was normal.
- She has attained menopause 7 yr back.
- She has 2 children of age 30 and 28 yrs.

Family history:

not relevant.

Drug history:

No history of continuous use of drugs except for the Inj mixtard.

- Provisional diagnosis on the basis of history:
 1. Acute pancreatitis
 2. Diabetic ketoacidosis
 3. Acute cholecystitis

General physical examination:

Patient is obese.

She has no pallor, icterus, clubbing, cyanosis, generalized lymphadenopathy or edema.

Vitals:

- Pulse: 118 bpm, regular and low volume
- Temperature: 98.8 degree Fahrenheit
- Respiratory rate: 28 cycles/min, rapid and shallow pattern
- Blood pressure: 100/60 mmHg

Local examination of abdomen:

Inspection:

- Shape of the abdomen is flat
- Umbilicus is normal in shape
- Flanks are normal
- No dilated veins or visible peristalsis
- Hernial orifices are normal

Palpation:

- No local rise of temperature
- Tenderness and muscle guarding over the epigastric region is present
- No swelling is palpable
- No organomegaly is noted

Percussion:

- Normal liver dullness is noted.

Auscultation:

- Bowel sounds are sluggish.

Systemic examination:

- Cardiovascular system: JVP normal
S1 and S2 heard,
no added sounds
- Respiratory system: B/L air entry present,
normal vesicular breath sounds,
no added sounds
- Central nervous system: no FND

Investigations:

CBP:

- Hb: 11.3 mg/dl
- TLC: 14,500 cells/cc
- Differential count:
Neutrophils 76%
Lymphocytes 16%
Eosinophils 05%
Monocytes 03%
Basophils 00%
- Platelets 2.4lakhs/cc
- PCV 41%

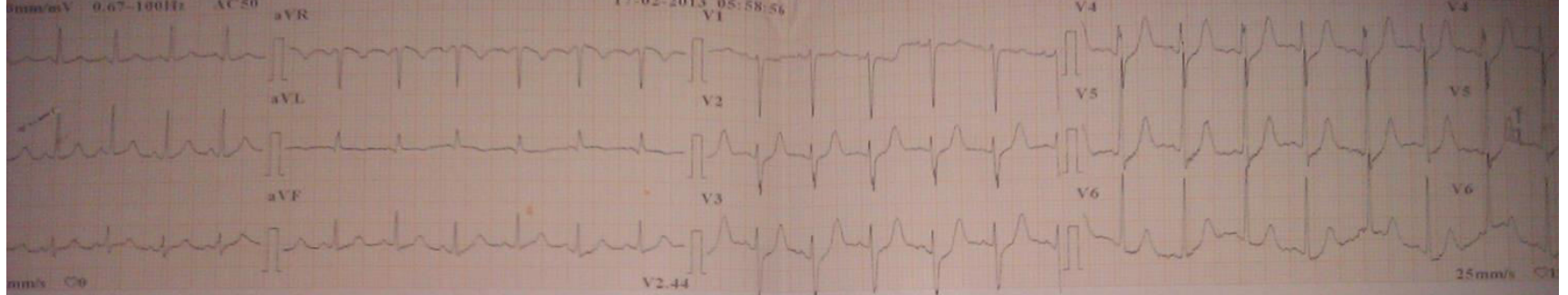
CUE:

- Urine sugar 3+
- Urine albumin 2+
- 2-3 pus cells/hpf
- 2-3 epithelial cells/hpf

10mm/mV 0.67-100Hz AC50

17-02-2013 05:58:56

10mm/mV



mm/s

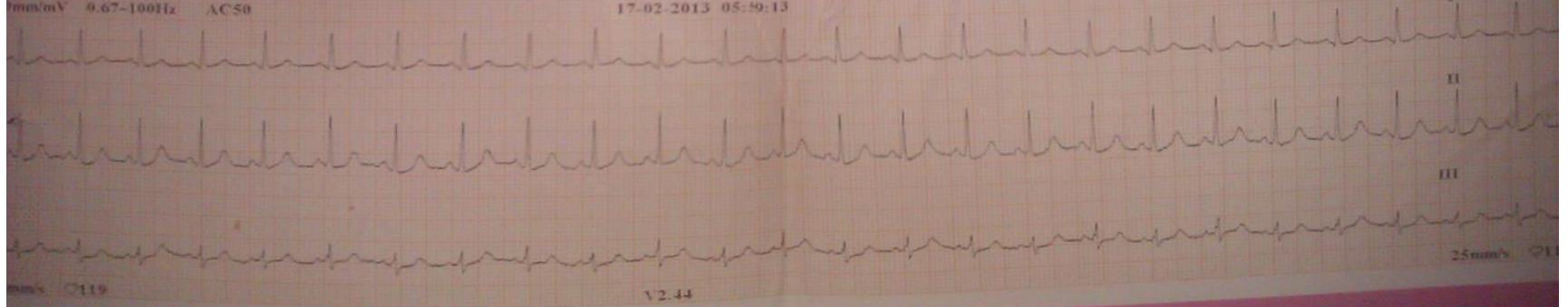V2.44

25mm/s

10mm/mV 0.67-100Hz AC50

17-02-2013 05:59:13

10mm/mV

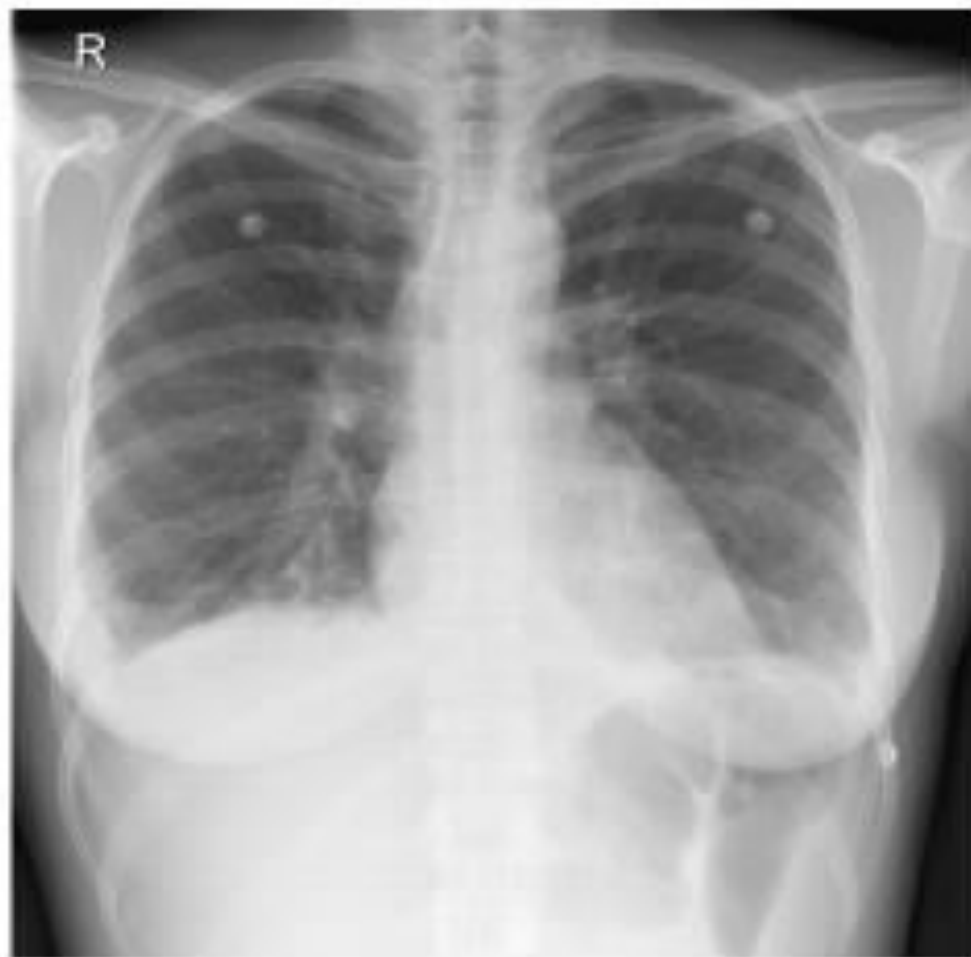

mm/s

V2.44

25mm/s

Chest x ray



- RBS: 524 mg/dl
- Urinary ketones: positive
- Blood urea: 56 mg/dl
- Serum creatinine: 1.1 mg/dl
- Serum electrolytes:

Sodium: 128 mEq/L

Potassium: 5.3 mEq/L

Chloride: 101 mEq/L

ABG:

- pH: 7.2
- pCO₂: 19 mmHg
- pO₂: 90 mmHg
- HCO₃: 10.1 mmol/L
- *Serum amylase: 72 IU/L*
- *Serum lipase: 140 IU/L*
- *Serum calcium: 9.8 mg/dl*

LFT:

- Total bilirubin: 1.1 mg/dl
- Direct: 0.31 mg/dl
- AST: 32 U/L
- ALT: 38U/L
- ALP: 84 U/L
- Total protein: 7 mg/dl
- Albumin: 3.3mg/dl
- A/G ratio: 1.1

- USG abdomen: **Acute pancreatitis.**

- **Diagnosis:**

Acute pancreatitis associated with Diabetic ketoacidosis.

Management:

Day 1:

- Nil per orally
- Ryles tube aspiration of gastric contents
- O2 inhalation 4lit/min
- IV fluids NS 15ml/kg/hr for 2hrs f/b 300ml/hr for next 2hrs
- Inj human actrapid insulin 0.1units/kg iv stat f/b 0.1units/kg/hr
- GRBS hrly.
- Stop the insulin drip when GRBS <200mg/dl and start neutralization drip 2 pint 5%D each with 5 units insulin @ 75ml/hr
- Inj ciprofloxacin 500 mg iv BD
- Inj metrogyl 500 mg iv TID
- Inj zofer 4mg iv BD
- Inj Buscopan 20mg im BD
- Input/output charting
- Serum K+ 4.9 mEq/L

Fasting lipid profile:

- *Serum triglycerides: 1073 mg/dl*
- serum LDL: 121 mg/dl
- Serum HDL: 46 mg/dl
- Serum cholesterol: 239 mg/dl

CECT abdomen: *Acute pancreatitis with necrosis*
<30%

MCTSI 3/10

Diagnosis:

Acute pancreatitis associated with diabetic ketoacidosis and hypertriglyceridemia.

Patient conscious, coherent
PR: 98 bpm, regular, normal
volume
BP: 110/70 mmHg
RS: BAE+, No added sounds
CVS: JVP normal, s1,s2 present

Serum K+ 4.9 mEq/L
Repeat ABG is normal
I/O: 2000/1800 ml

Day 2:

- Nil per orally
- O2 inhalation 3lit/min
- GRBS hrly
- IV fluids 3 pint NS @ 150 ml/hr
- IV fluid 1 pint 5%D with 5units of actrapid insulin
- Inj ciprofloxacin 500 mg iv BD
- Inj metrogyl 500 mg iv TID
- Inj zofer 4mg iv BD
- Inj Buscopan 20mg im BD
- Monitor BP hrly

Patient conscious, coherent
PR: 92 bpm, regular, normal
volume

BP: 110/70 mmHg

RS: BAE+, No added sounds

CVS: JVP normal, s1,s2
present

Serum K+ 4.6mEq/L

I/O: 2300/2100 ml

Day 3:

- Started oral feeding with liquid diet
- Inj human actrapid insulin s.c. 14units TID
- GRBS before each insulin injection
- Inj ciprofloxacin 500 mg iv BD
- Inj metrogyl 500 mg iv TID
- Inj zofer 4mg iv SOS
- Inj Buscopan 20mg im BD
- Tab Atorlip-F 20/160 mg OD H/S
- Input/output charting
- Monitor BP 6th hrly

Patient conscious, coherent
PR: 92 bpm, regular, normal
volume

BP: 110/70 mmHg

RS: BAE+, No added sounds

CVS: JVP normal, s1,s2
present

Day 4:

- Started oral feeding with soft diet
- Inj human mixtard insulin s.c. 15 units in the morning and 10units in the night
- GRBS three times a day
- Inj ciprofloxacin 500 mg iv BD
- Inj metrogyl 500 mg iv TID
- Inj zofer 4mg iv SOS
- Inj Buscopan 20mg im sos
- Tab atorlip-F 20/160 mg OD H/S
- Monitor BP 8th hrly
- Plenty of oral fluids

Patient conscious, coherent

PR: 90 bpm, regular, normal volume

BP: 110/80 mmHg

RS: BAE+, No added sounds

CVS: JVP normal, s1,s2 present

Day 5:

- oral feeding with soft diet
- Inj human mixtard 15U in the morning and 10U in the night half an hour before food
- GRBS three times a day
- Inj ciprofloxacin 500 mg iv BD
- Inj metrogyl 500 mg iv TID
- Inj zofer 4mg iv SOS
- Inj Buscopan 20mg im SOS
- Tab Atorlip-F 20/160mg OD H/S
- Plenty of oral fluids

Day 6 to day 10:

- oral feeding with soft diet
- Inj human mixtard 15U in the morning and 10U in the night half an hour before food
- GRBS three times a day
- Tab ciprofloxacin 500 mg iv BD
- Tab metrogyl 400 mg iv TID
- Tab pantop 40mg OD
- Tab Atorlip-F 20/160 mg OD H/S
- Plenty of oral fluids

CASE-2

- A 30 year old male patient resident of ramannapet has come to the casualty with chief complaints of pain abdomen since 1 day.

History of present illness:

- Abdominal pain is epigastric and periumbilical in region, radiating to the back and chest, dull and aching in nature, not related to food.
- He is having a binge of alcohol from the last 2 days

- He has no history of jaundice and no history of abdominal distension.
- No h/o constipation or loose stools.
- No h/o fever, vomiting, headache.

Past history:

- He has no history of similar complaints in the past.
- He is not a known case of diabetes, hypertension, tuberculosis, asthma, epilepsy.
- He has no history of gall stone disease.
- No history of previous surgeries.

Personal history:

- He is a known smoker since 10 years and smokes 5 cigarettes per day.
- He is a known alcoholic and consumes 2 pints of beer 3 to 4 times a week.
- Bowel and bladder habits are regular.
- Appetite is normal.

Drug history:

- No history of continuous use any drugs.

Family history:

- Not relevant

Provisional diagnosis:

- Acute pancreatitis
- Acute appendicitis

General physical examination:

- Patient is well built and moderately nourished.
- He has no pallor, icterus, clubbing, cyanosis, generalized lymphadenopathy or edema.

Vitals:

- Pulse: 102 bpm, regular, normal in volume.
- Temperature: 98.9 degree Fahrenheit
- Respiratory rate: 20/ min
- Blood pressure: 110/70 mmHg

Local examination of the abdomen:

Inspection:

- Shape of the abdomen is scaphoid
- Umbilicus is normal in shape
- Flanks are normal
- No dilated veins or visible peristalsis
- Hernial orifices are normal

Palpation:

- No local rise of temperature
- Tenderness and muscle guarding is present diffusely
- No swelling is palpable.
- No organomegaly is noted.

Percussion:

Normal liver dullness is noted.

Auscultation:

- Bowel sounds are present

Systemic examination:

- Cardiovascular system: JVP normal
S1 and S2 heard,
no added sounds
- Respiratory system: B/L air entry present,
normal vesicular breath sounds
no added sounds
- Central nervous system: no FND

Investigations:

CBP:

- Hb: 12.5 mg/dl
- Total count: 13,200 cells/cc
- Differential count:

Neutrophils 79%

Lymphocytes 11%

Eosinophils 06%

Monocytes 03%

Basophils 01%

- Platelets: 1.9 lakhs/cc
- PCV 39%

CUE:

- Urine sugar nil
- Urine albumin nil
- 2-3 pus cells/hpf
- 2-3 epithelial cells/hpf

- RBS: 112 mg/dl
- Blood urea: 42 mg/dl
- Serum creatinine: 1.0 mg/dl
- Serum electrolytes:
Sodium: 141 mEq/L
Potassium: 3.9mEq/L
Chloride: 104 mEq/L
- *Serum amylase: 365 IU/L*
- *Serum lipase: 410 IU/L*
- *Serum calcium: 9.6 mg/dl*

LFT:

- Total bilirubin: 1.6 mg/dl
 - Direct: 0.34 mg/dl
 - AST: 71 U/L
 - ALT: 43 U/L
 - ALP: 94 U/L
 - Total protein: 6 mg/dl
 - Albumin: 3mg/dl
 - A/G ratio: 1.0
-
- USG abdomen: Acute pancreatitis.
 - CECT abdomen: Acute pancreatitis with necrosis <30%
MCTSI 3/10.

- **DIAGNOSIS:**

Acute pancreatitis due to alcoholism

Treatment:

Day 1:

- Nil per orally
- Ryles tube aspiration of gastric contents
- O2 inhalation 3lit/min
- Inj ciprofloxacin 500 mg iv BD
- Inj metrogyl 500 mg iv TID
- Inj zofer 4mg iv SOS
- Inj Buscopan 20mg im BD
- IV fluids 2 pint NS and 2 pint RL @ 150 ml/hr
- IV fluid 2 pint DNS and 1 pint 25%D @ 150ml/hr
- I/O charting

Patient conscious, coherent

PR: 96 bpm, regular, normal volume

BP: 120/80 mmHg

RS: BAE+, No added sounds

CVS: JVP normal, s1,s2 present

Day 2:

- Nil per orally
- Inj ciprofloxacin 500 mg iv BD
- Inj metrogyl 500 mg iv TID
- Inj pantop 40mg iv OD
- Inj Buscopan 20mg im BD
- IV fluids 1 pint NS and 1 pint RL @ 100 ml/hr
- IV fluid 2 pint DNS and 2 pint 5%D @ 100ml/hr

Patient conscious, coherent
PR: 100 bpm, regular, normal volume
BP: 120/80 mmHg
RS: BAE+, No added sounds
CVS: JVP normal, s1,s2 present

Day 3:

- Started oral feeding with liquid diet
- Inj ciprofloxacin 500 mg iv BD
- Inj metrogyl 500 mg iv TID
- Inj pantop 4mg iv OD
- Inj Buscopan 20mg im BD
- IV fluids 1 pint NS at 50 ml/hr

Patient conscious, coherent
PR: 98 bpm, regular, normal volume
BP: 120/80 mmHg
RS: BAE+, No added sounds
CVS: JVP normal, s1,s2 present

- Day 4 and 5:
- Started oral soft diet
- Inj ciprofloxacin 500 mg iv BD
- Inj metrogyl 500mg iv BD
- Inj pantop 40mg iv OD
- Inj Buscopan 20 mg im OD
- Plenty of oral fluids

Day 6 to 8:

- Tab ciprofloxacin 500 mg iv BD
- Tab metrogyl 400 mg iv TID
- Tab pantop 40mg OD
- Plenty of oral fluids

Thank you