

CASE PRESENTATION

Dr.SWATHI SHENISHETTY

III YEAR PG

DEPT. OF OPHTHALMOLOGY



CASE 1

- Name : Baby of Mrs.XX
- Postnatal age - 4weeks (postconceptional age – 32weeks)
- Sex : Female
- Resident of : Devarakonda
- Informant : Mother



Was sent for ROP screening

- Birth weight : 1.31kg
- Gestational age : 28 weeks
- Type of delivery : Normal Vaginal Delivery
- Baby cried immediately after birth



- History of mechanical ventilation for 10days
- History of Neonatal Jaundice present for which Phototherapy was given
- No history of blood transfusion



Maternal history:

- Age of mother : 20yrs
- Non-consanguinous marriage, married life – 2yrs

Ante natal history:

- Primi, with regular antenatal check ups
- No history of any maternal illness

Natal history:

- Spontaneous Normal vaginal delivery at 28weeks

Postnatal history: Uneventful



General Examination :

- Afebrile
- Pulse : 140 BPM
- Respiratory rate : 50 /min
- CVS : S1, S2 heard
- Respiratory system : Bilateral Air Entry +
- CNS : Normal
- Per abdomen : Soft



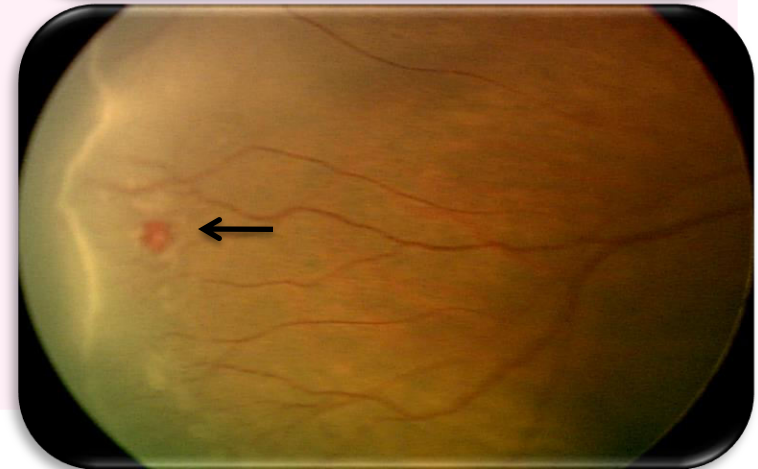
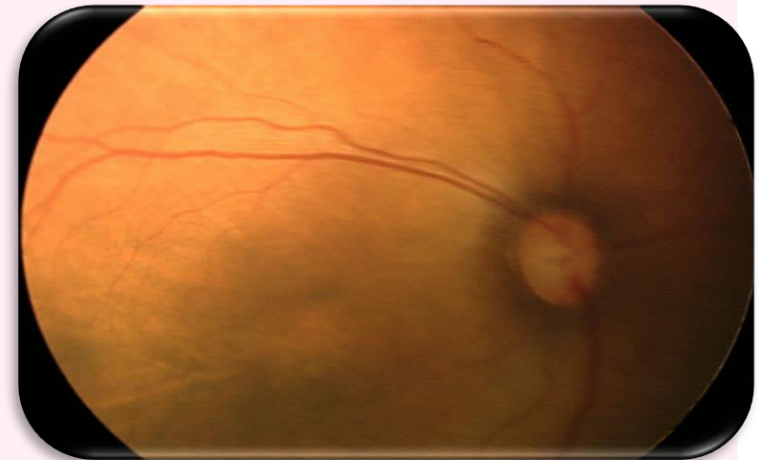
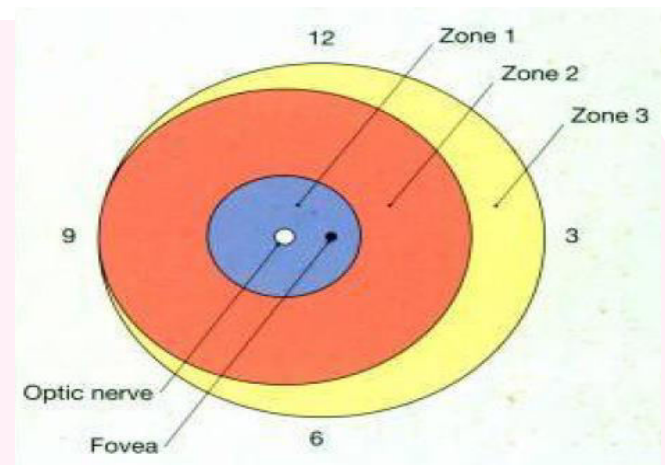
Ocular Examination :

	RIGHT EYE	LEFT EYE
Lids	Normal	Normal
Conjunctiva	Normal	Normal
Cornea	Clear	Clear
Anterior chamber	Normal depth	Normal depth
Iris	Normal color and pattern	Normal color and pattern
Pupil	Normal size, sluggishly reacting to light	Normal size, sluggishly reacting to light
Lens	Transparent	Transparent



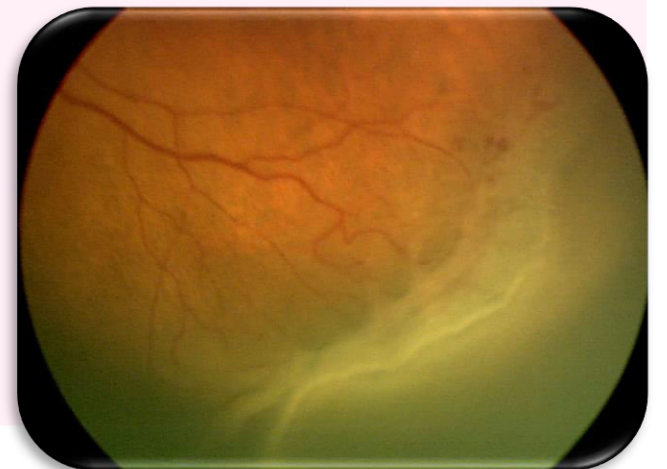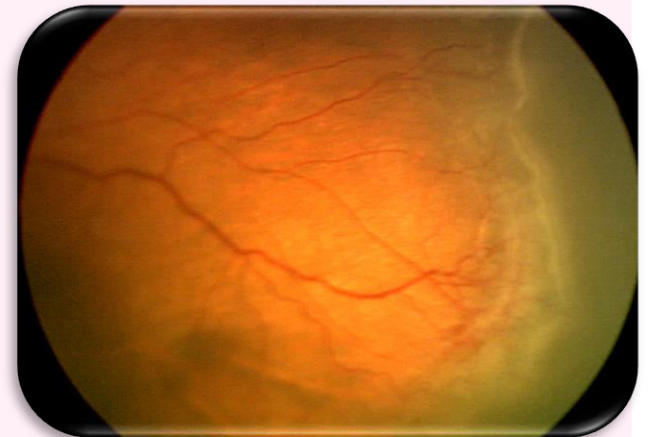
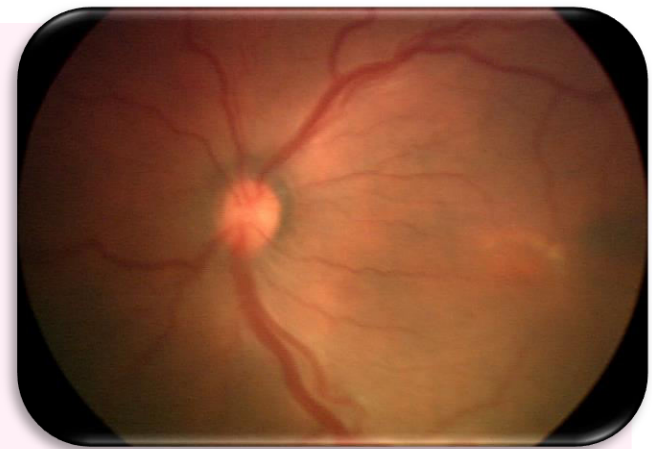
Indirect Ophthalmoscopy :

	RIGHT EYE
MEDIA	Vitreous haze present
DISC	Normal
VESSELS	Tortuous arteries, dilated veins in supero temporal and infero temporal quadrants
MACULA	Normal
PERIPHERY	White, tortuous, ridge seen in the temporal retina from 6 to 11 o'clock Blood vessels entering the ridge and into the vitreous Tuft of small wavy vessels seen – new vessels With vitreous hemorrhage



Indirect Ophthalmoscopy :

	LEFT EYE
MEDIA	Vitreous haze present
DISC	Normal
VESSELS	Tortuous arteries, dilated veins in all quadrants
MACULA	Normal
PERIPHERY	White, tortuous, ridge seen in the temporal retina from 1 to 6 o'clock Blood vessels entering the ridge and into the vitreous A tuft of small wavy vessels seen – new vessels Fibro vascular proliferation seen



Differential Diagnosis:

- Retinopathy of prematurity
 - Familial exudative retinopathy
 - Incontinentia pigmenti
 - Norrie's disease
 - Persistent fetal vasculature
 - Coats' disease
- No history of prematurity
- Unilateral



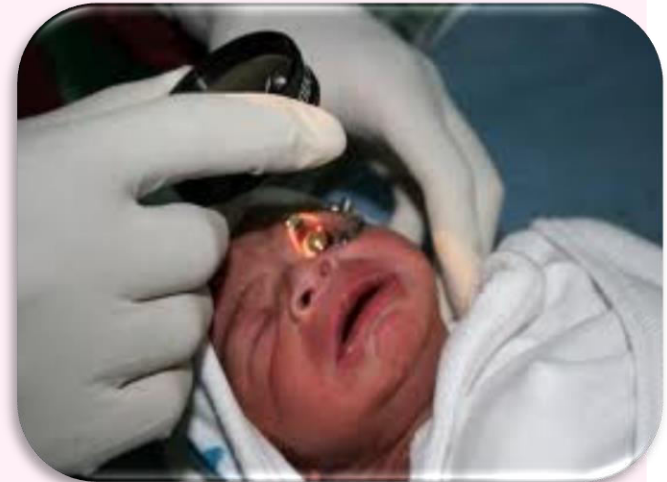Provisional Diagnosis :

Right eye : Zone II, Stage 3 + Retinopathy of Prematurity (Type 1 Pre-Threshold disease)

Left eye : Zone II, Stage 3 + Retinopathy of Prematurity (Threshold disease)

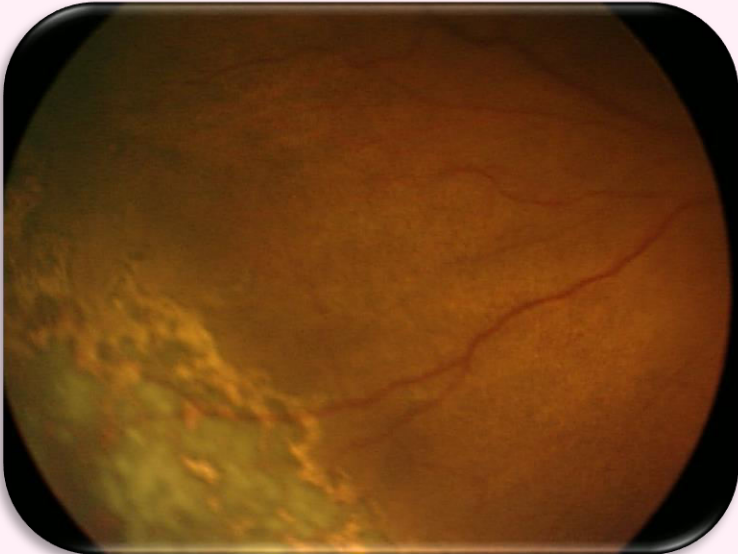
Treatment:

- Both eyes : Laser Photocoagulation with Diode laser under TA was given
- Follow up at weekly intervals till signs of regression appear

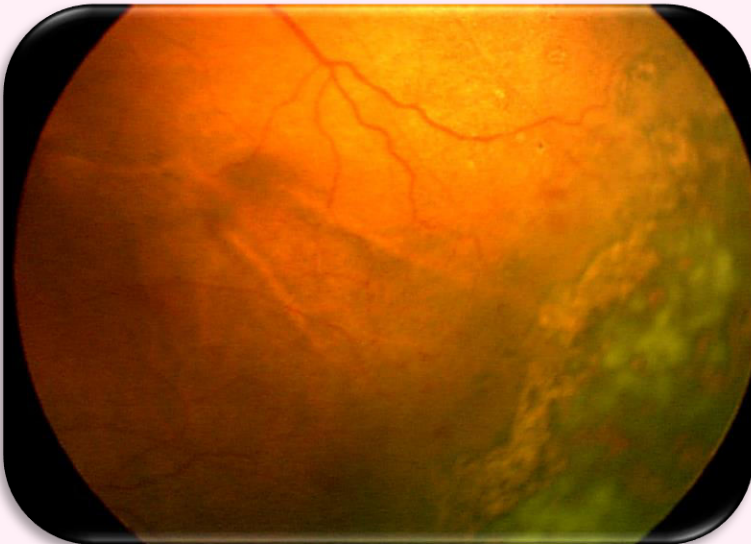


Follow up

Right eye



Left eye



CASE 2

- Name : Baby of Mrs. X
- Post natal age – 3weeks (postconceptional age – 33weeks)
- Sex : Male
- Resident of : Lingojigudem
- Informant : Mother



Was sent for ROP screening

- Gestational age : 30 weeks
- Birth weight : 1.25kg
- Type of delivery : LSCS
- Baby cried immediately after birth
- History of NICU admission for 10 days



- History of Neonatal Jaundice present for which Phototherapy was given for 3 days
- No history of blood transfusion
- No history of mechanical ventilation



Maternal History :

- Age of mother : 22yrs
- Non-consanguinous marriage, married life – 2yrs

Antenatal history:

- Primi, with regular antenatal check ups
- History of PIH in 3rd trimester

Natal history:

LSCS at 30weeks gestation

Post –natal history:

Uneventful



General Examination :

- Afebrile
- Pulse : 136 BPM
- Respiratory rate : 50 /min
- CVS : S1, S2 heard
- Respiratory system : Bilateral Air Entry +
- CNS : Normal
- Per Abdomen : Soft



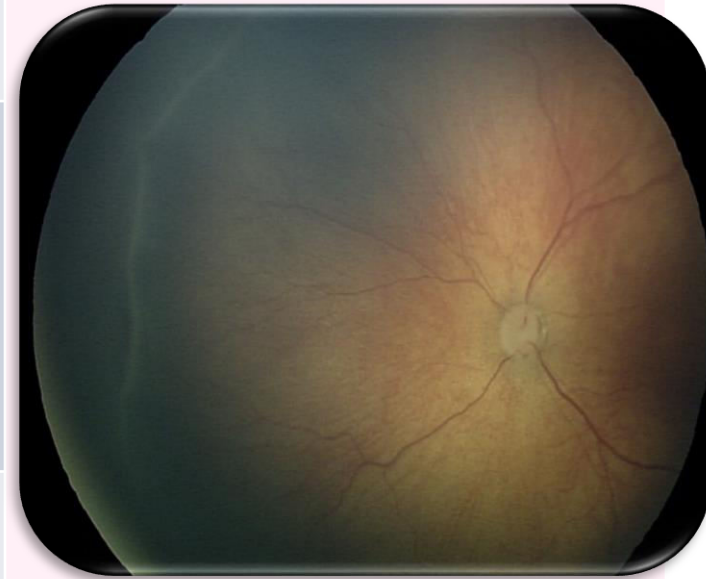
Ocular Examination :

	RIGHT EYE	LEFT EYE
Lids	Normal	Normal
Conjunctiva	Normal	Normal
Cornea	Clear	Clear
Anterior chamber	Normal depth	Normal depth
Iris	Normal color and pattern	Normal color and pattern
Pupil	Normal size, reacting to light	Normal size, reacting to light
Lens	Transparent	Transparent



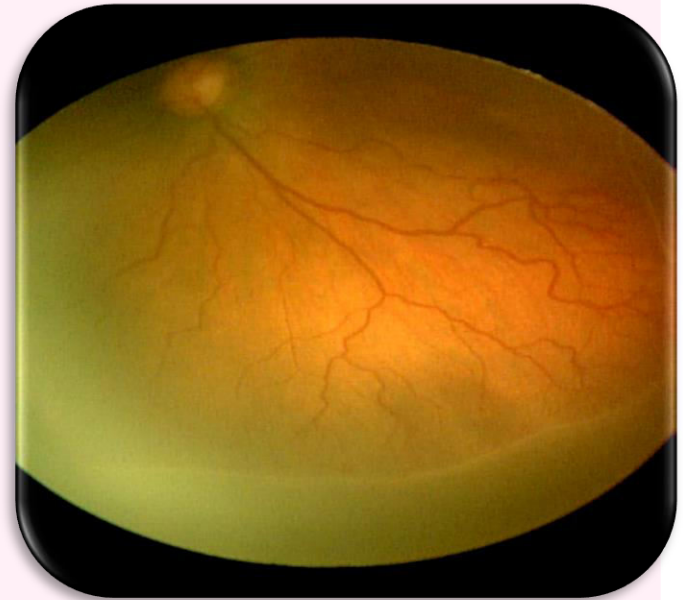
Indirect Ophthalmoscopy :

	RIGHT EYE
MEDIA	Clear
DISC	Normal
VESSELS	Nasal retina – normal vasculature seen Incomplete vascularization of temporal retina
MACULA	Normal
PERIPHERY	Whitish, tortuous, ridge seen in the temporal retina From 7 to 11 o'clock



Indirect Ophthalmoscopy :

	LEFT EYE
MEDIA	Clear
DISC	Normal
VESSELS	Incomplete vascularization of inferotemporal retina
MACULA	Normal
PERIPHERY	White, tortuous, ridge seen in the inferotemporal retina from 4 to 7 o'clock



Provisional Diagnosis:

- Right eye : Zone 2, Stage 2 Retinopathy of Prematurity (4 clock hours)
- Left eye : Zone 2, Stage 2 Retinopathy of Prematurity (4 clock hours)

Treatment :

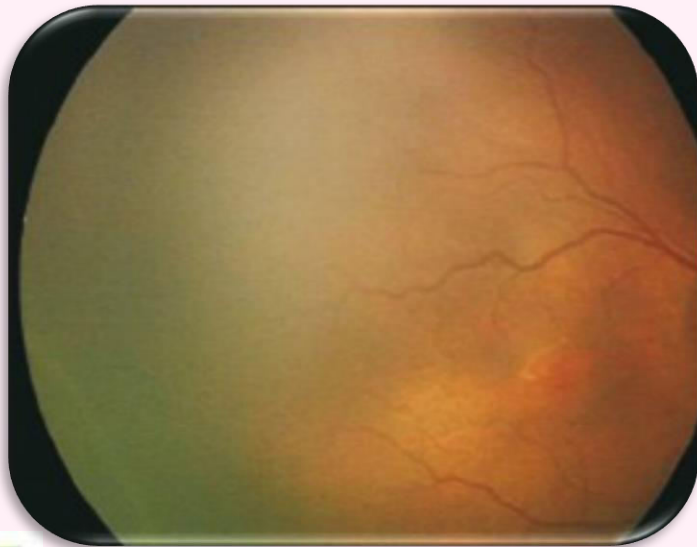
- Observation at 2weekly intervals till postconceptional age of 42weeks



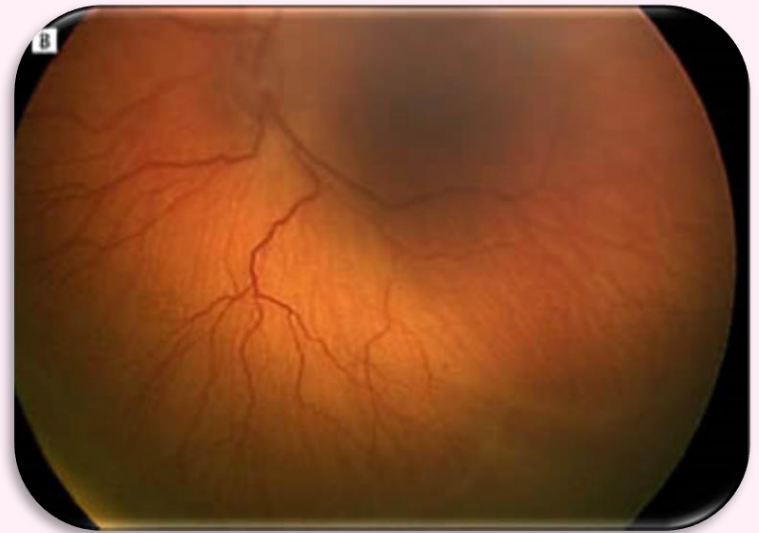
Follow Up :

- Spontaneous regression with normal Vascularization seen

Right Eye



Left Eye



Thank you

