

CASE PRESENTATION

-Dr V.Sreeteja

➤ Name : X X X X X

➤ Age : 65yrs

➤ Sex : Female

➤ Occupation : Housewife

➤ Residence : Chityal

- **CHIEF COMPLAINTS : -**

- Diminution of vision in Left Eye since 1 yr

- Pain, Redness and Watering in Left Eye since 2 days

HISTORY OF PRESENT ILLNESS:-

➤ Patient was apparently normal 1 yr back when she developed diminished vision in Left Eye which is

- Insidious in onset
- Gradually progressive
- Painless

➤ h/o Pain since 2 days which is

- Sudden in onset
- Continuous dragging type
- No aggravating factors
- Temporarily relieved on medication

➤ Associated with redness and watering in Left Eye since 2 days

- No h/o Ocular Trauma
- No h/o Photophobia
- No h/o Floaters/Flashes
- No h/o Coloured Haloes

PAST HISTORY:

- No h/o similar complaints in the past
- No h/o DM/HTN/Asthma/Drug allergy
- h/o Ocular surgery in Right Eye 6 months back-
uneventful-post operative vision 6/9
- No h/o usage of any topical medications

FAMILY HISTORY:

No h/o similar complaints in the family

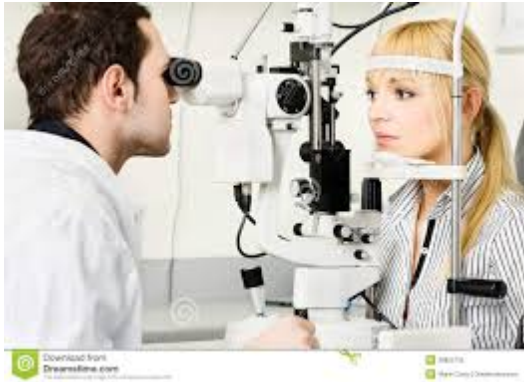PERSONAL HISTORY:

Diet-Mixed

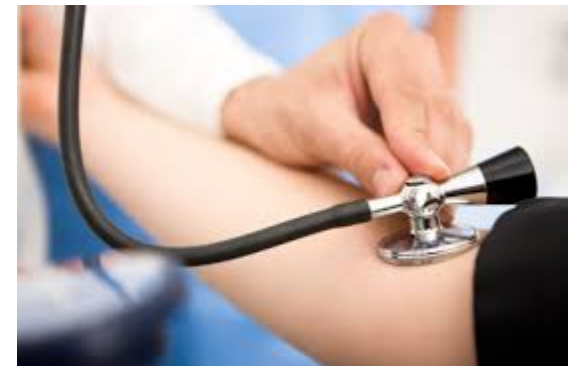Bowel and Bladder-Normal

Appetite-Good

Sleep-Undisturbed



EXAMINATION



GENERAL EXAMINATION

- Patient is conscious and coherent oriented to time,place and person
- Moderately built and nourished
- Vitals are normal

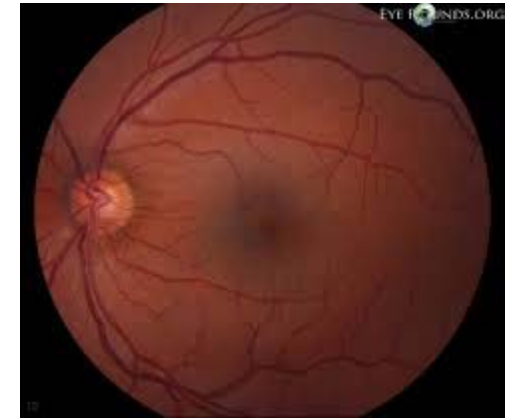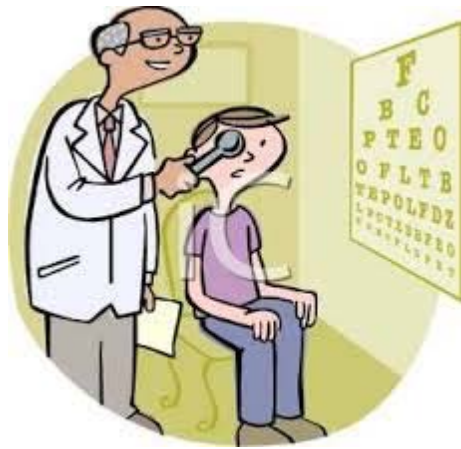SYSTEMIC EXAMINATION

- CVS – Normal
- Respiratory system – Normal
- CNS – Normal
- GIT - Normal

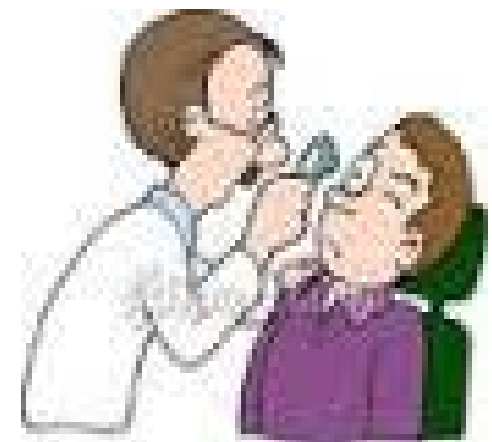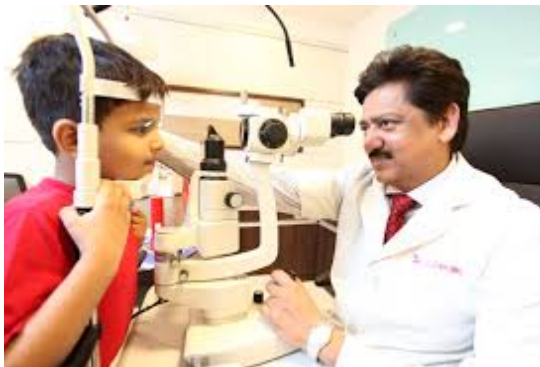Differential Diagnosis ?



- Keratitis
- Chronic Iridocyclitis
- Angle closure Glaucoma
- Secondary Glaucoma



OCULAR EXAMINATION



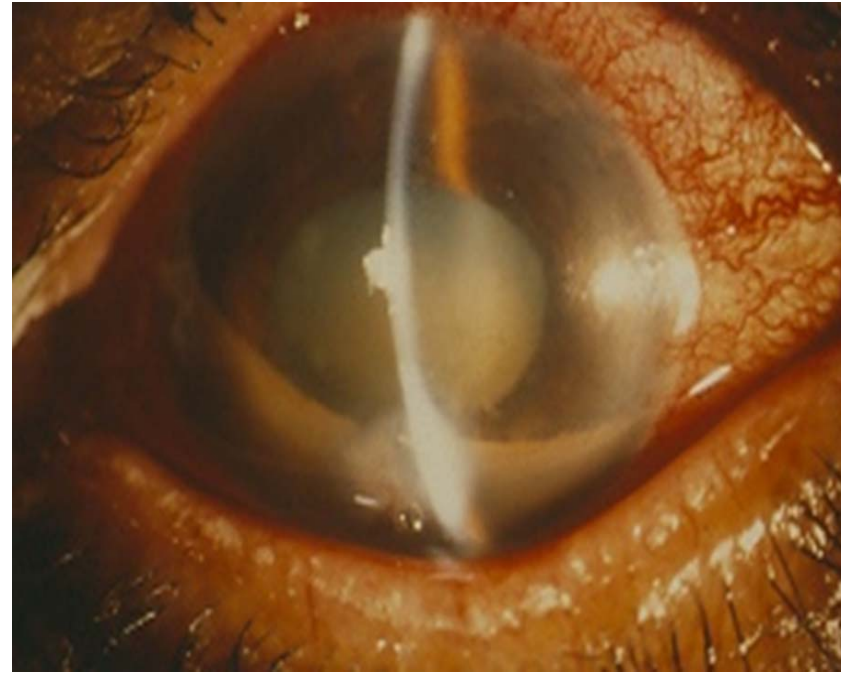
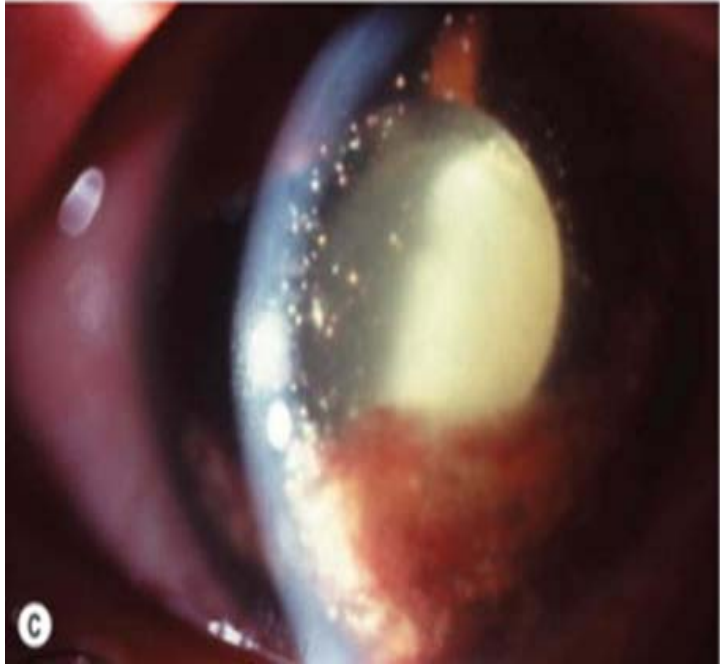	OD	OS
Visual acuity	6/9 PH 6/6	PL+ PR+ in all quadrants
Near vision	N6	-

- Head posture - Normal
- Facial symmetry – Maintained
- Ocular symmetry – Maintained
- Forehead – Normal
- Extra ocular movements – Full range in all directions

SLIT LAMP EXAMINATION

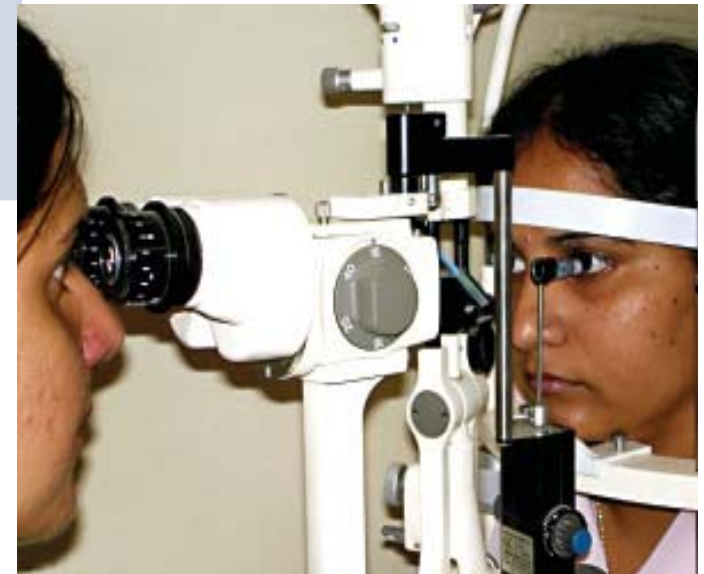	OD	OS
EYELIDS	Normal	Edema
CONJUNCTIVA	Normal	Circumciliary congestion
CORNEA	Normal in size,elliptical in shape,regular surface,transparent and normal corneal sensations	Normal in size,elliptical in shape ,regular surface,transparency is lost due to epithelial and stromal edema,white particles on endothelium and corneal sensations are normal
ANTERIOR CHAMBER	Normal depth, PACD=1/2 CT ,clear contents	Normal depth,PACD>1/2 CT White particles in Aqueous Flare +2 Cells +3 Pseudohypopyon

	OD	OS
IRIS	Normal pattern & colour	Appears Normal pattern & colour
PUPIL	3-4mm in diameter Brisk Reaction to Direct and Indirect Light	5mm in diameter, mid dilated and sluggish reaction to direct and indirect light
LENS	Pseudophakia	Milky white Opacification White particles over Anterior Capsule



INTRAOCULAR PRESSURE

	OD	OS
On the day of presentation at 11 AM With Applanation Tonometry	16 mm Hg	46 mm Hg



GONIOSCOPY

- **Right Eye :**

- Scleral Spur is seen in all quadrants
- Grade 3 (Shaffers Grading)
- No Peripheral Anterior Synechiae

- **Left Eye :**

- No view d/t Corneal edema

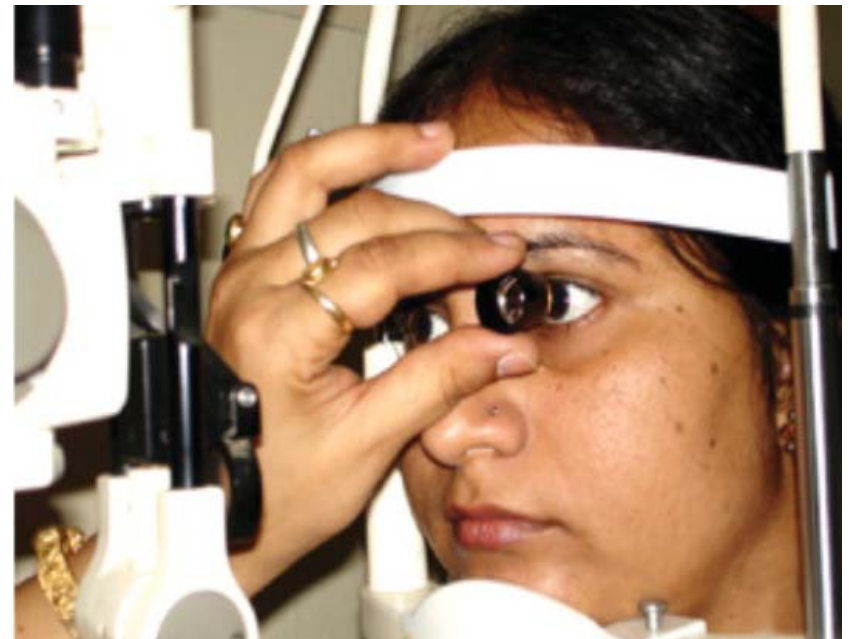Impression:

- Right Eye –

Open Angles in all quadrants

- Left Eye-

No view



FUNDUS EXAMINATION

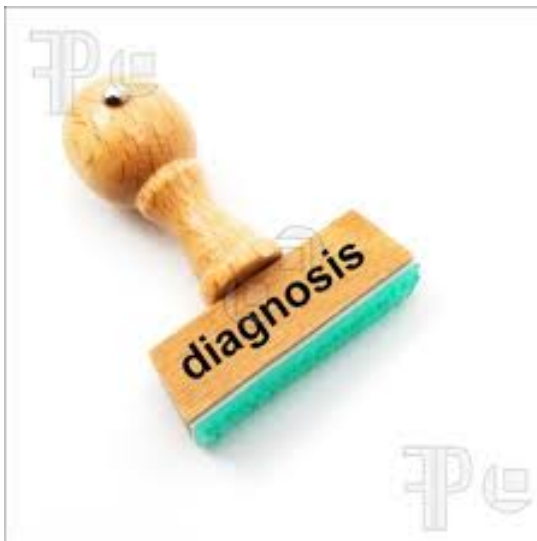	OD	OS
Media	Clear	No View due to corneal edema
Disc	Normal in size, Pink, Circular, Well defined margins CDR-0.3:1	-
Vessels	Normal A:V Ratio-2:3	-
Macula	Normal FR-Dull	-
Periphery	Normal	-

DIAGNOSIS



© Can Stock Photo - csp11890168

What is the probable diagnosis?



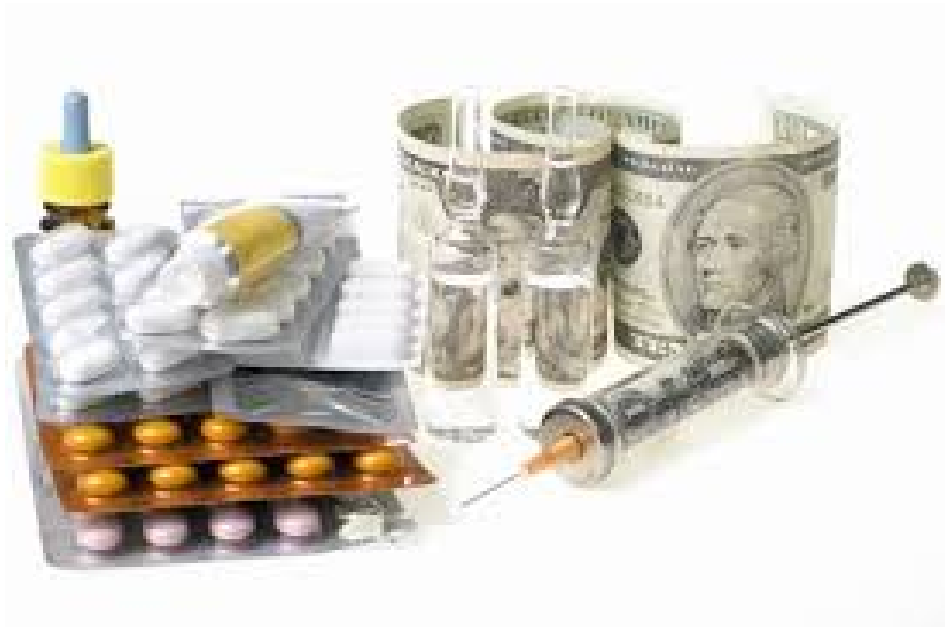➤ **RE** - Pseudophakia

•

•

➤ **LE** - Lens induced Secondary Glaucoma (Phacolytic Glaucoma)

TREATMENT



PLAN OF TREATMENT

- **Definitive Treatment:**

Lens Extraction with Posterior Chamber Intraocular Lens Implantation after reducing IOP

- **Medical treatment:**

- Inj. Mannitol 20% i.v stat
- Tab. Acetazolamide 250 mg BD
- E/D Timolol maleate 0.5% BD
- E/D Prednisolone acetate 1% hrly

ON THE NEXT DAY

- **INTRA OCULAR PRESSURE**

	OD	OS
On next day at 8 AM With Goldmann Applanation Tonometry	14 mm Hg	23mm Hg

•GONIOSCOPY

Left Eye :

- Scleral Spur is seen in all quadrants
- Grade 3(Shaffers Grading)
- No Peripheral Anterior Synechiae

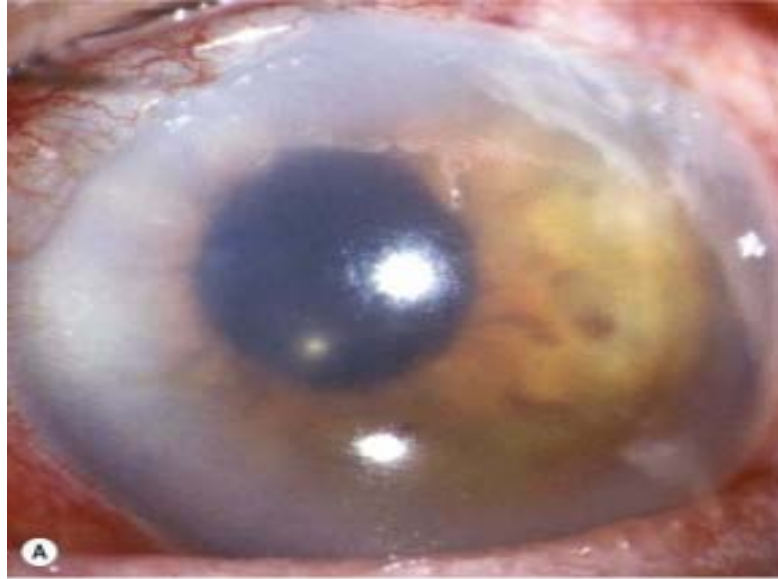Impression: Open Angles in all quadrants

SURGICAL TREATMENT

- Small Incision Cataract Surgery with Posterior Chamber Intraocular Lens Implantation under Local Anaesthesia on 15/04/15

POST OPERATIVE DAY -1

	OD	OS
Lids	Normal	Mild edema
Conjunctiva	Normal	Mild Congestion
Cornea	Clear	Mild Diffuse edema
AC	Normal depth	Flare +1 Cells +1
Pupil	NSRL	NSRL
Lens	Pseudophakia	Pseudophakia



2016-1-19

- Treatment :Tab Ibuprofen +Paracetamol BD
E/D Ciprofloxacin D hrly

POST OPERATIVE VISION

Visual acuity	OD	OS
1 St POD	6/9	6/12

POST OPERATIVE IOP LEVELS

	OD	OS
On 1 st POD at 11 AM with Goldmann Applanation Tonometry	12 mm of Hg	16 mm of Hg

AFTER ONE WEEK

	OD	OS
Lids	Normal	Normal
Conjunctiva	Normal	Normal
Cornea	Clear	Clear
AC	Normal depth	Normal depth
Pupil	NSRL	NSRL
Lens	Pseudophakia	Pseudophakia

POST OPERATIVE VISION

Visual acuity	OD	OS
	6/9	6/9

POST OPERATIVE IOP LEVELS

	OD	OS
22/5/15 at 11 AM with Goldmann Applanation Tonometry	12 mm of Hg	14 mm of Hg

THANK YOU